

Case studies of the Orthopedic Walk-in Clinic

Andrew J. Beverly PA-C, ATC

* Nothing to disclose.

Case #1

- * High school senior presents from Queens, New York
- * Recent spider bite on his hand
- * Works as a photographer part-time
- * No previous issues with this
- * Wakes up the day after the spider bite with significant muscle soreness
- * Unknown spider type/origin



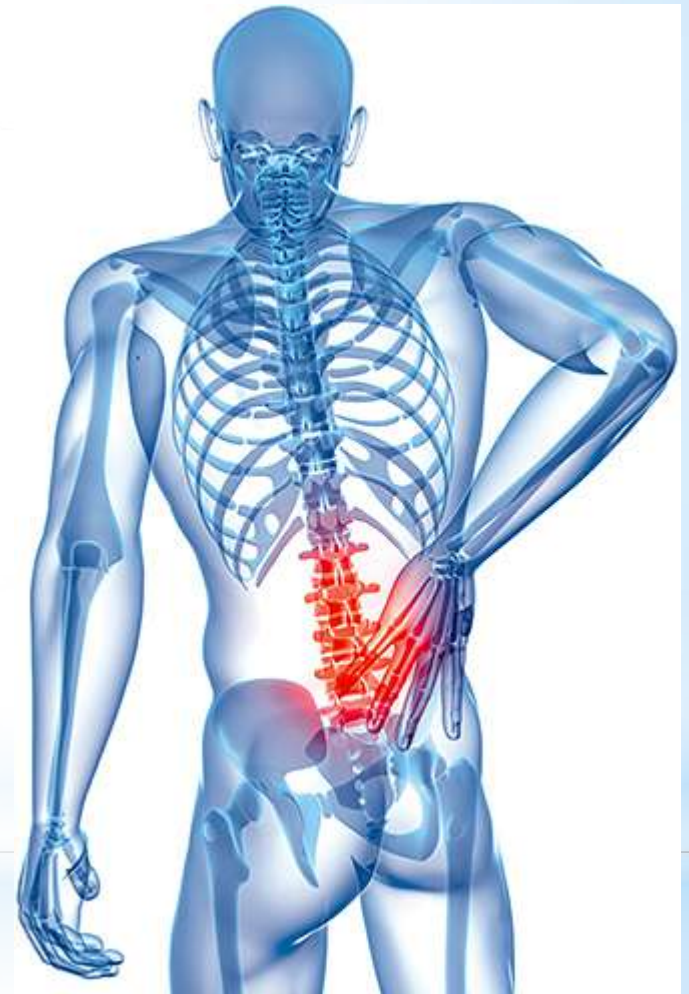Case #1

- * Thankfully, patient did bring video of the incident

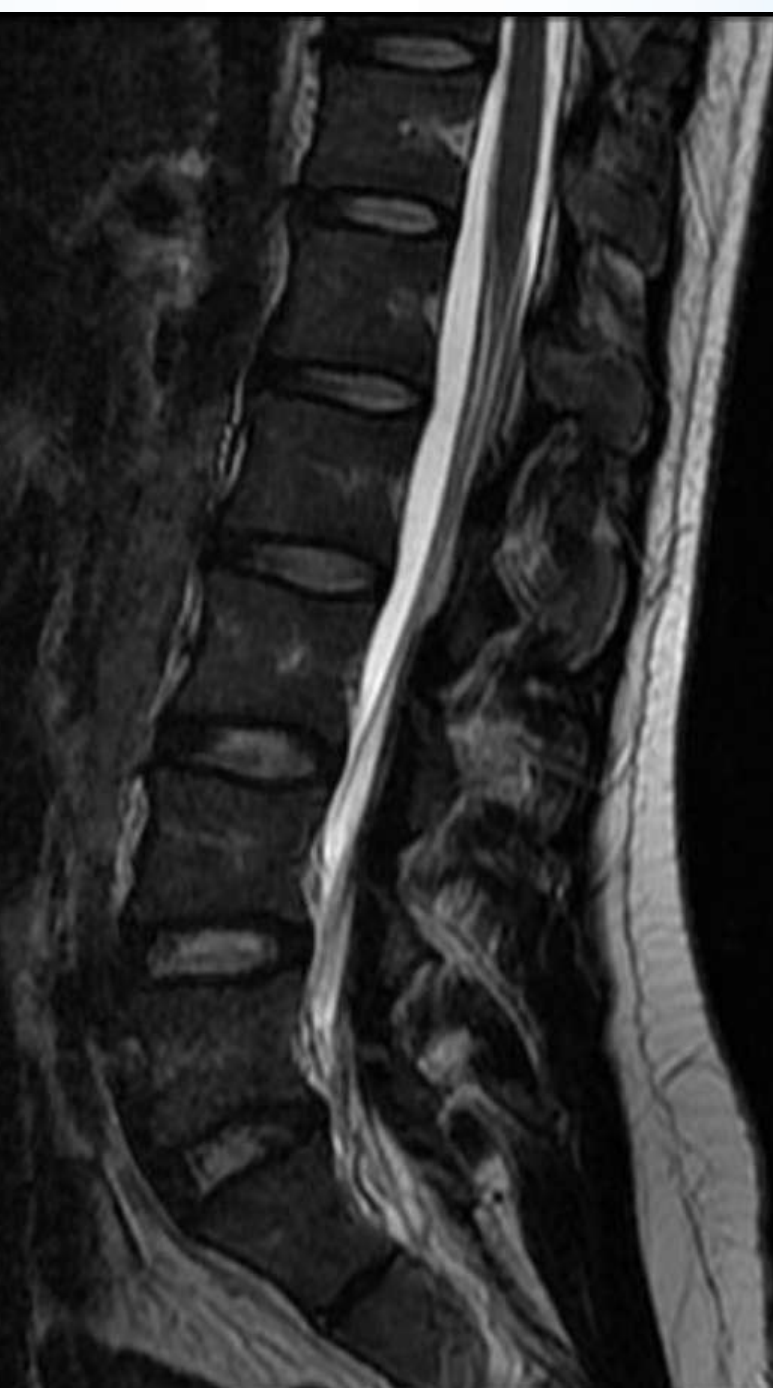

Real Case #1

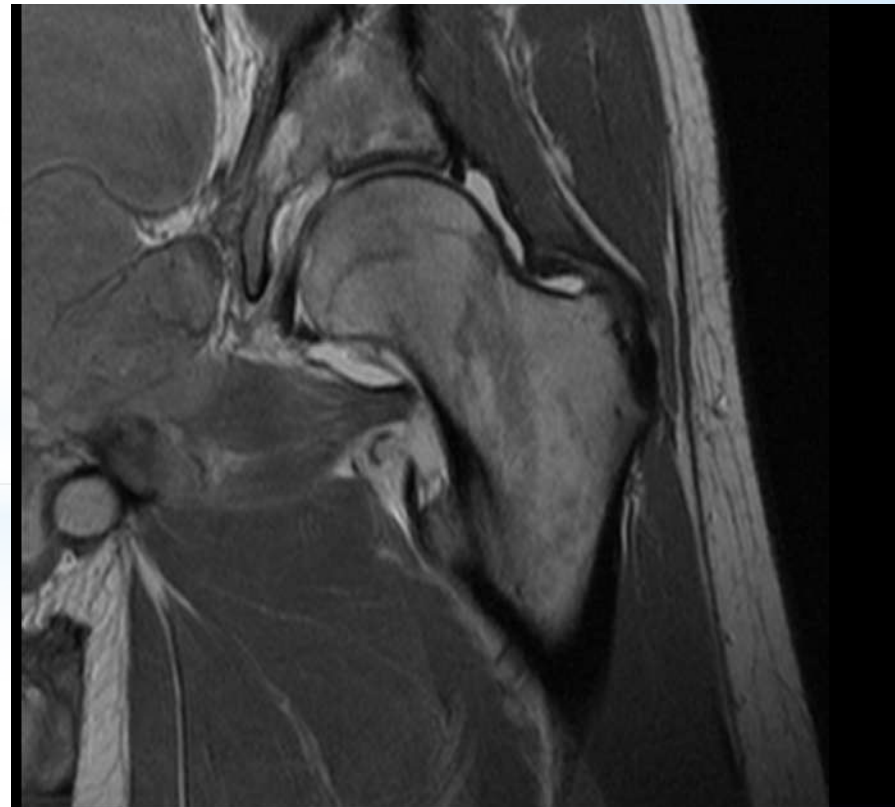
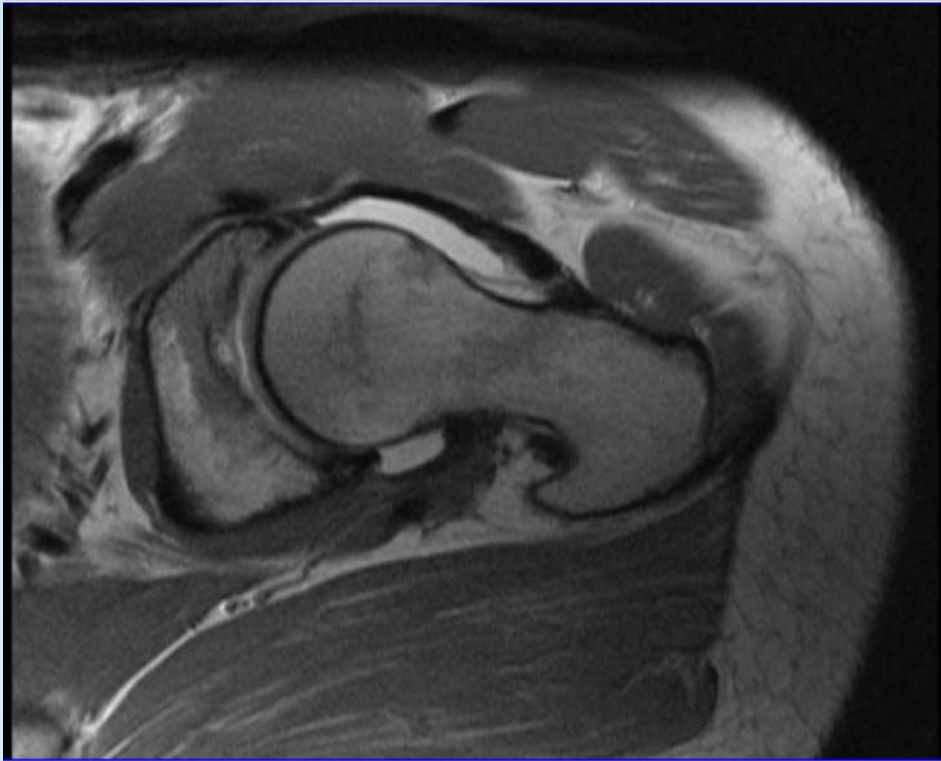
- * 26-year-old male, one year of persistent low back and hip pain following MVA.
- * Original MRI of the lumbar spine showed multiple small bulging discs, mostly central and mild foraminal stenosis
- * 1 year of treatment has consisted of medicine, chiropractic adjustments, PT, multiple ER trips due to pain.
- * Comes in for second opinion, referral to spine surgeon

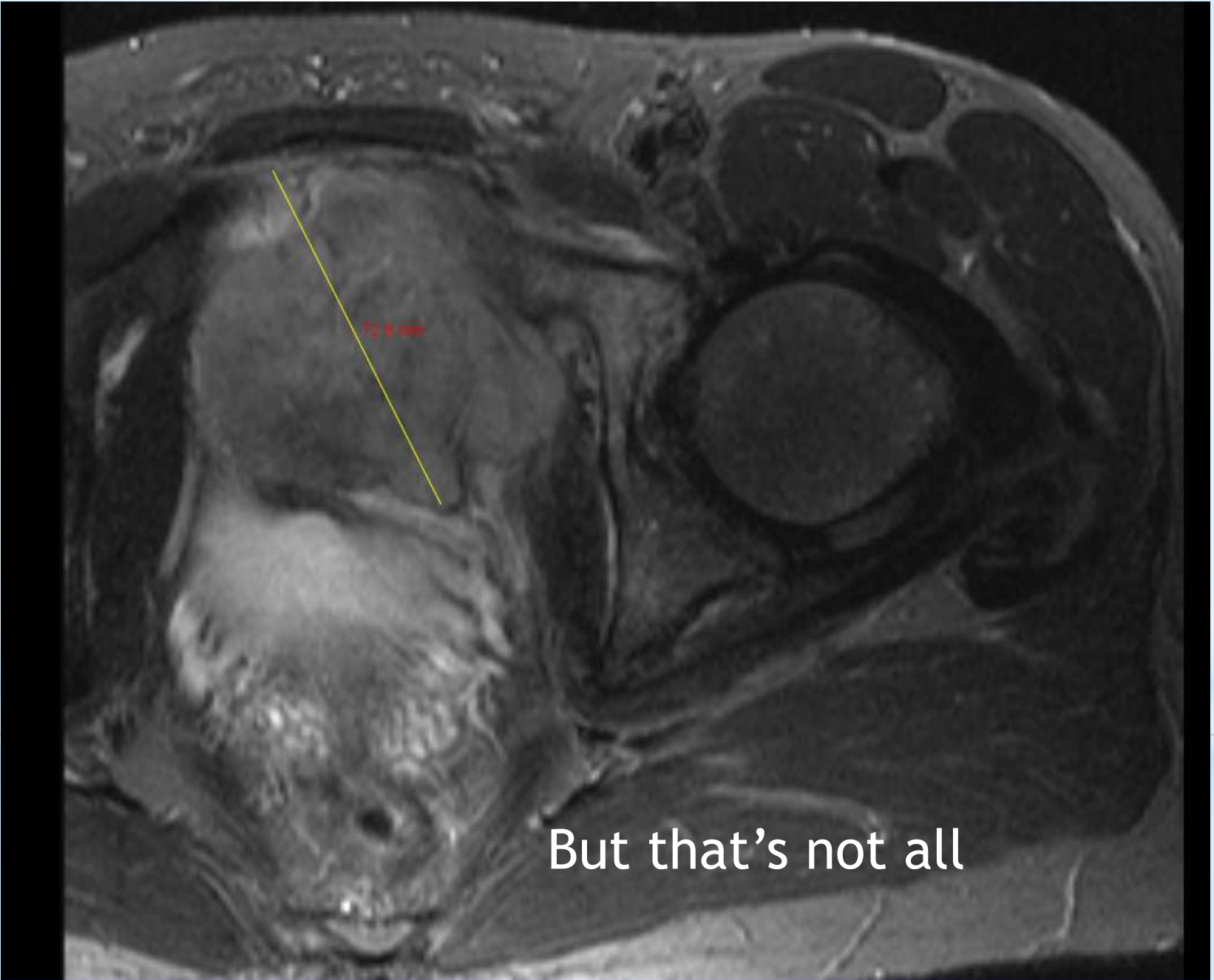


- * This is the MRI we treated for a year with no relief
- * Patient still has 10/10 pain
- * Exam is off-the-charts aggravated, specifically on hip exam.
- * Thinking more hip, maybe labral tear

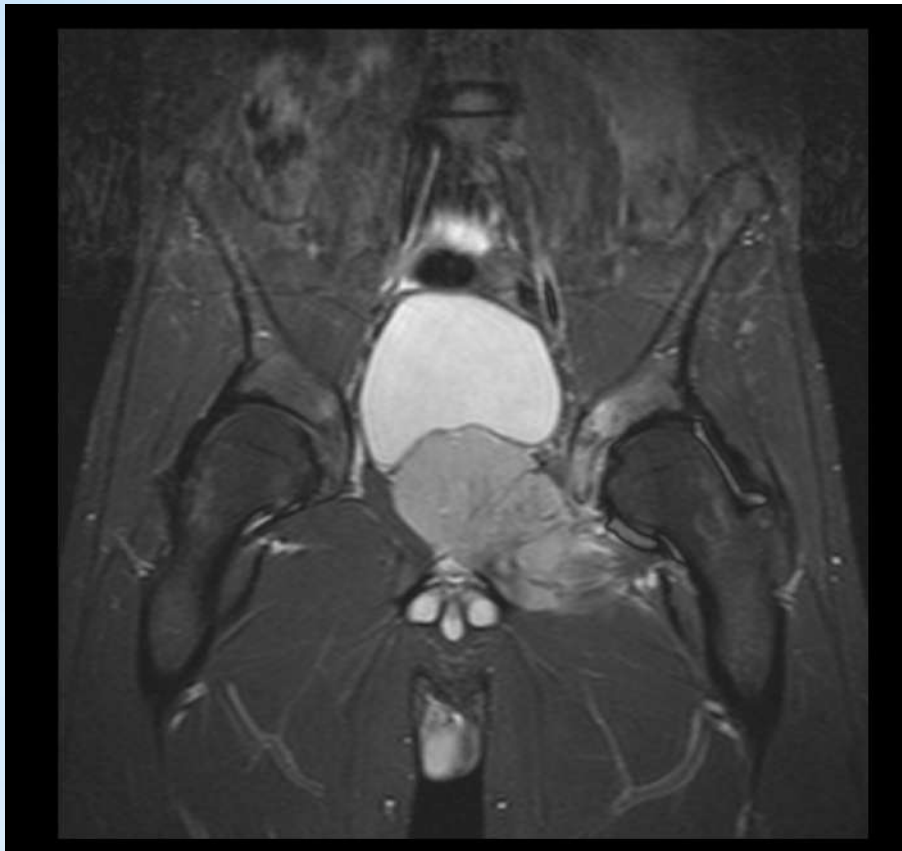


* He did have a labral tear!





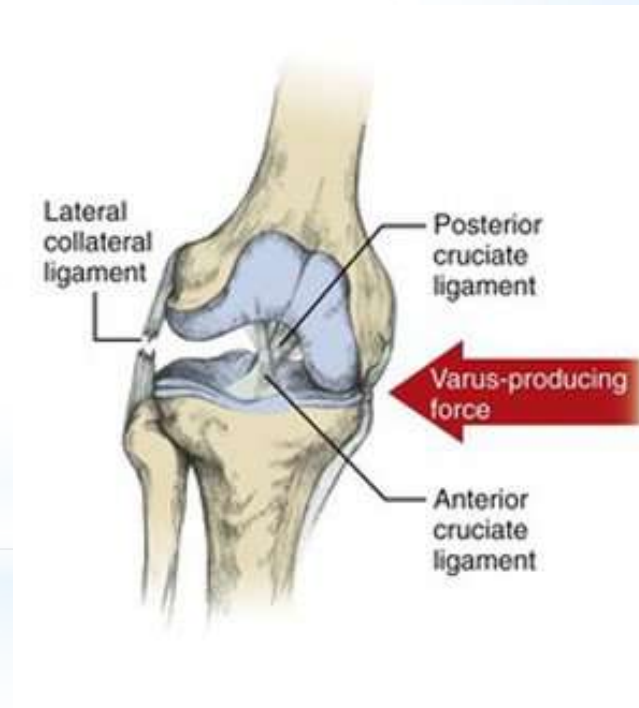
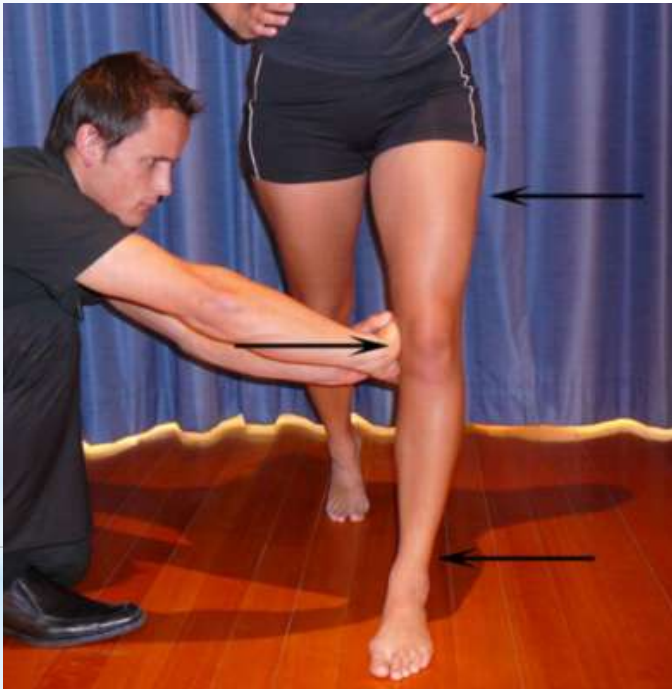But that's not all




- * Large heterogenous mass in the obturator foramen with lytic lesions in the pubic symphysis.
- * Most likely sarcoma, Ewing's sarcoma or osteosarcoma
- * Referred to Ortho oncology-Jacksonville
- * Biopsy unknown
- * Lost to follow-up

Red flag takeaway:
Pain out of proportion with exam/imaging may necessitate further work-up.

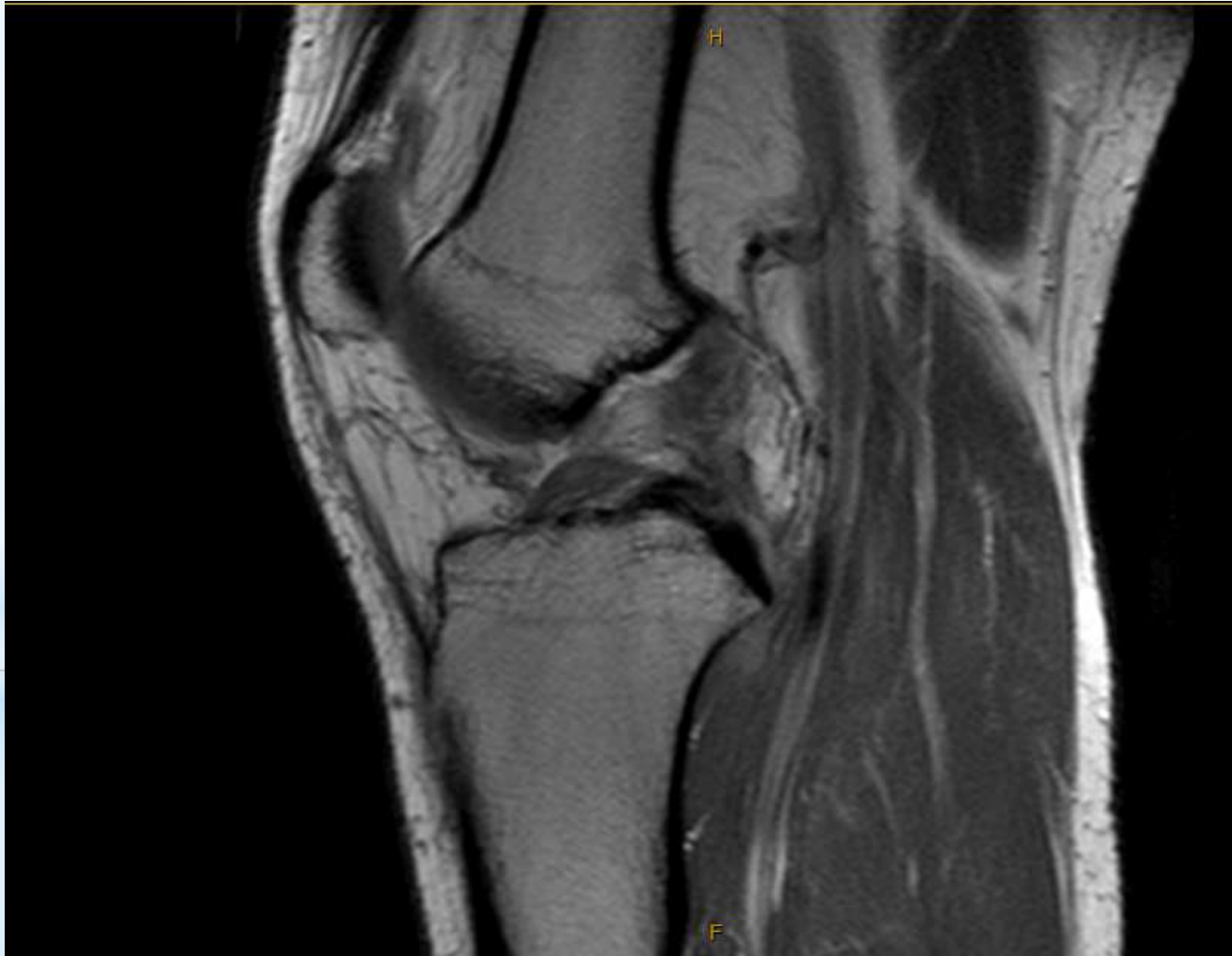- * 18-year-old male
- * High school football injury
- * Non-contact cutting injury, followed by varus force



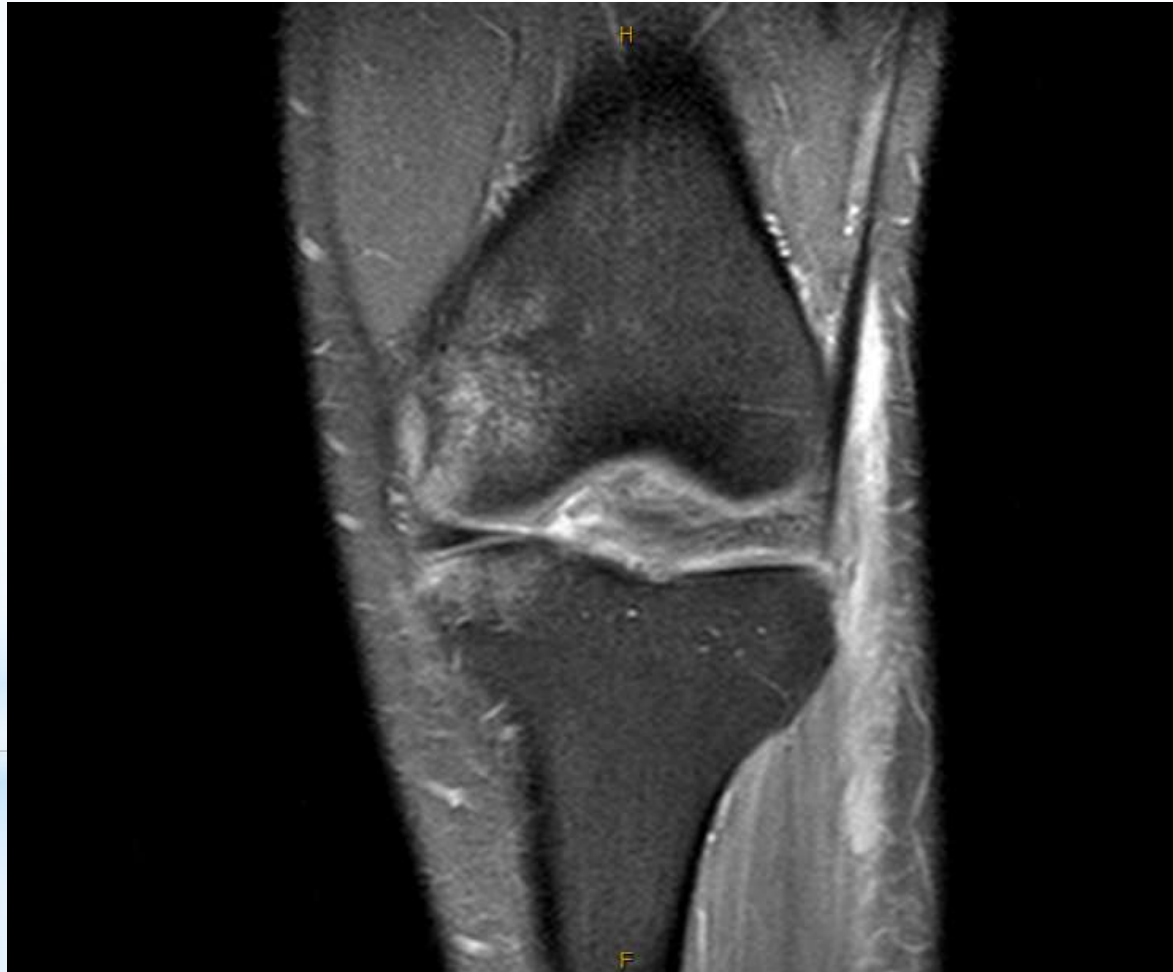
- * Significant laxity
- * Lateral joint line gapping
- * Assess distal pulses
- * Check ankle dorsiflexion
- * Splint on-field
- * ER exam-fracture, stability, vascular/nerve damage



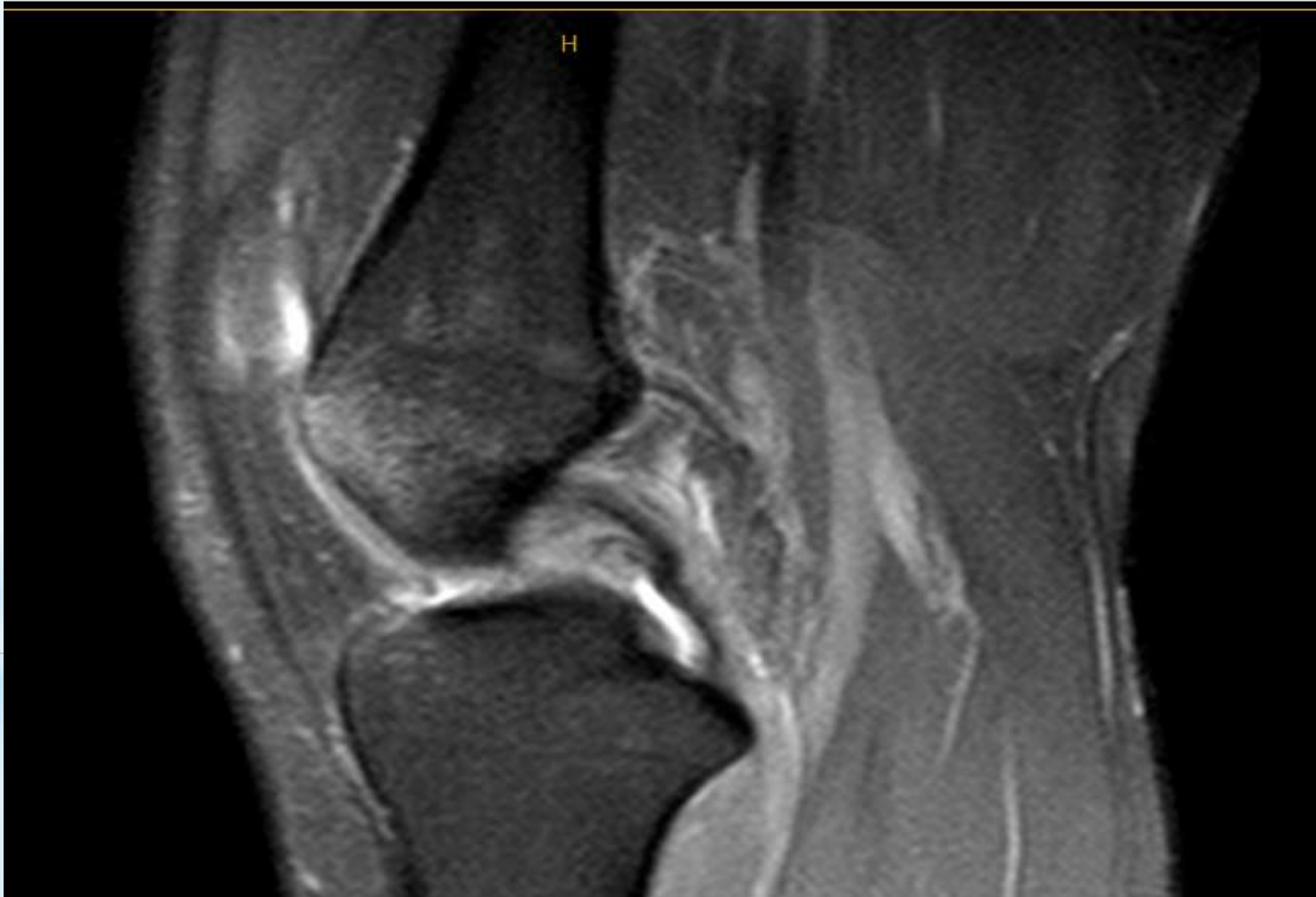* ACL:Mush



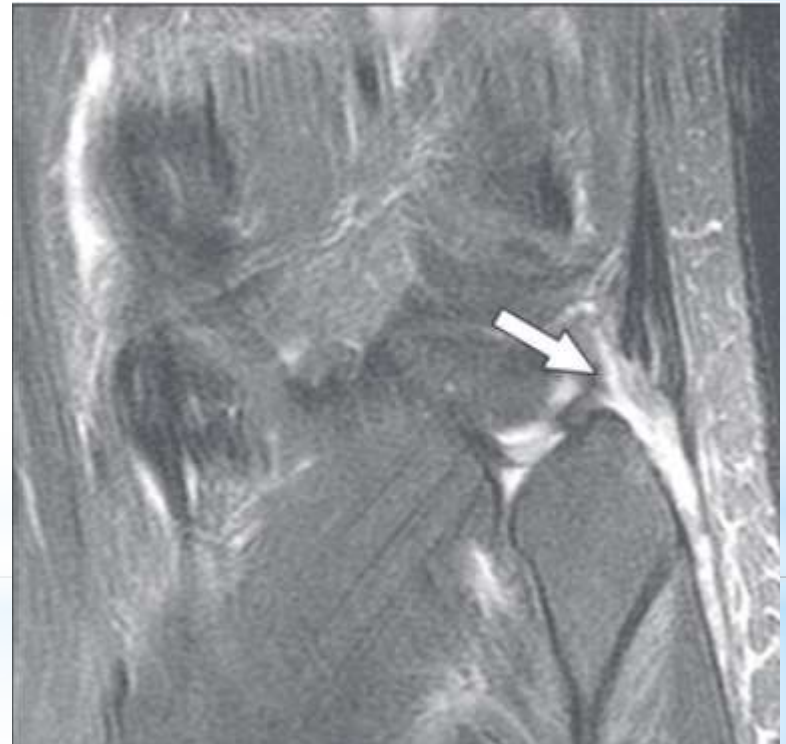
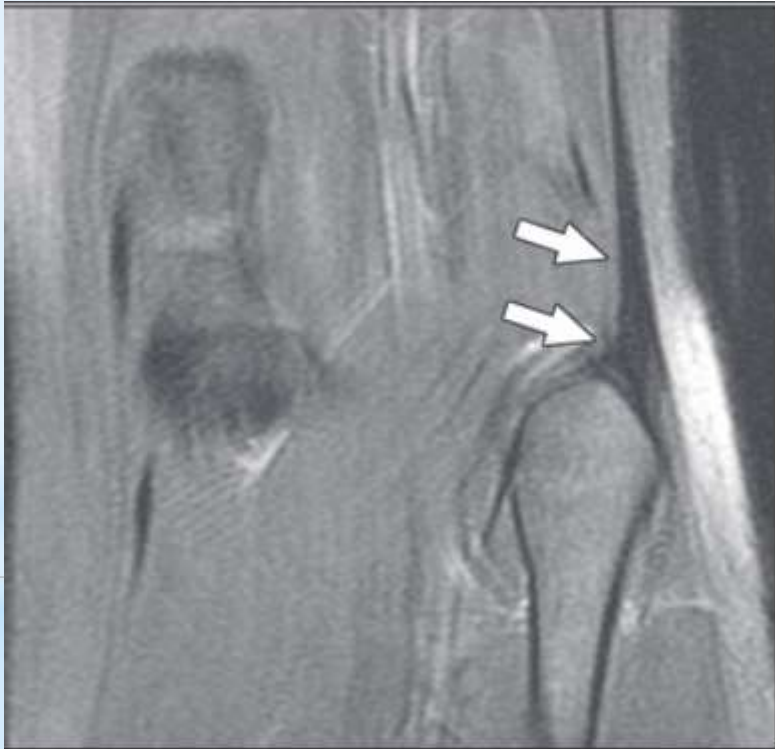* Medial Bone bruise pattern



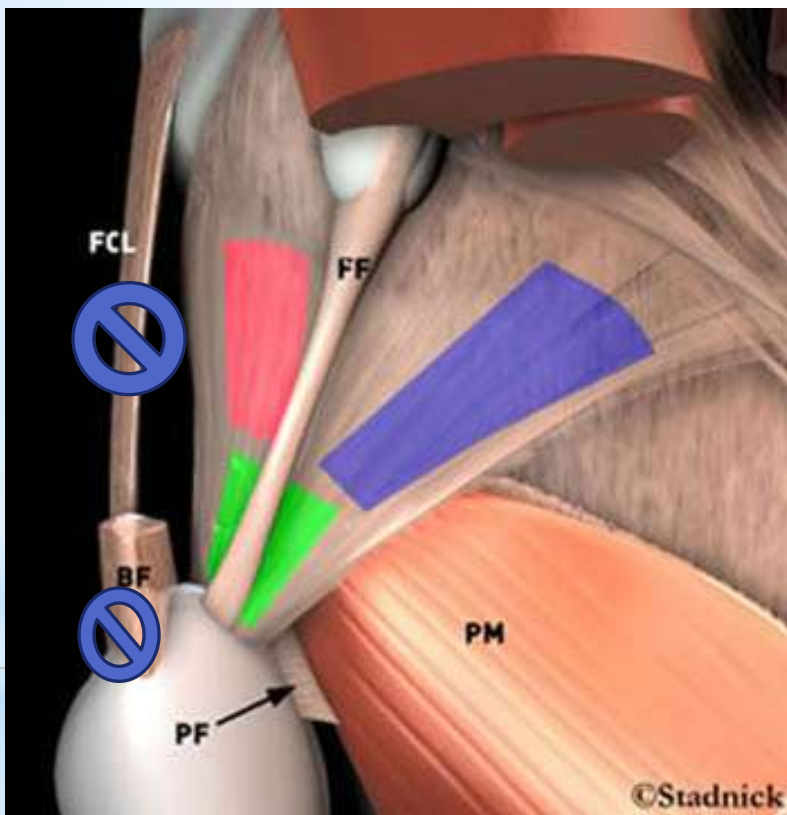
*PCL: incongruent



*Posterolateral Corner injury



*Posterolateral corner



4

Figure 4:(4a) Biceps femoris muscle and tendon removed demonstrates the Y-shaped arcuate ligament composed of the medial (blue) and lateral (red) limbs and its attachment (green) to the fibular styloid process. The biceps femoris tendon (BF), fibular collateral ligament (FCL), fabellofibular ligament (FF), popliteofibular ligament (PF), and popliteus muscle (PM) are also demonstrated.

- * 62% of PCL injuries associated with posterolateral corner(1)
- * Debatably, #1 cause of ACL repair re-rupture is undiagnosed/treated posterolateral corner injury.
- * Without ligament damage, untreated PLC injury can lead to OA
- * Dial test

DIAL Test
Posterolateral Rotatory Instability

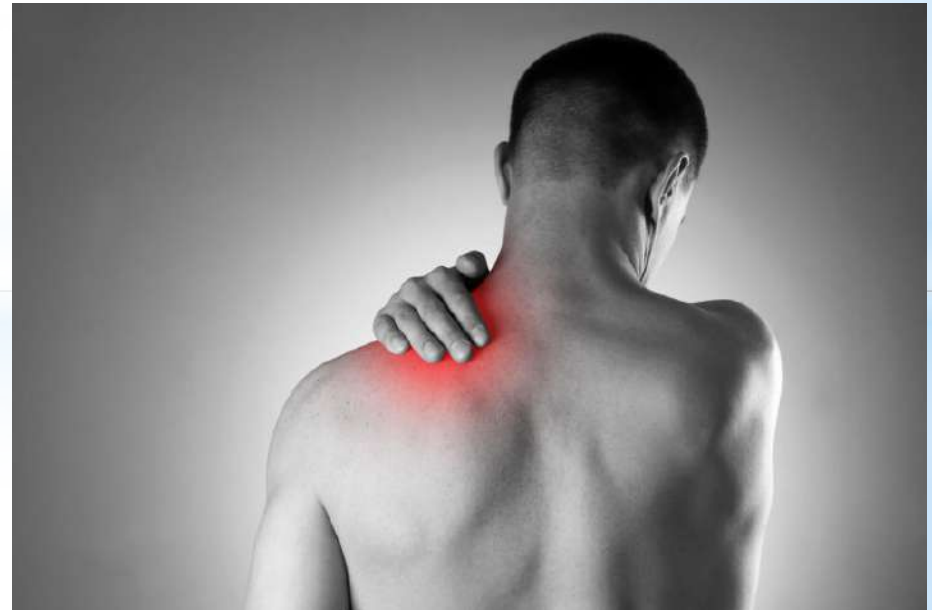Source: CR Technologies

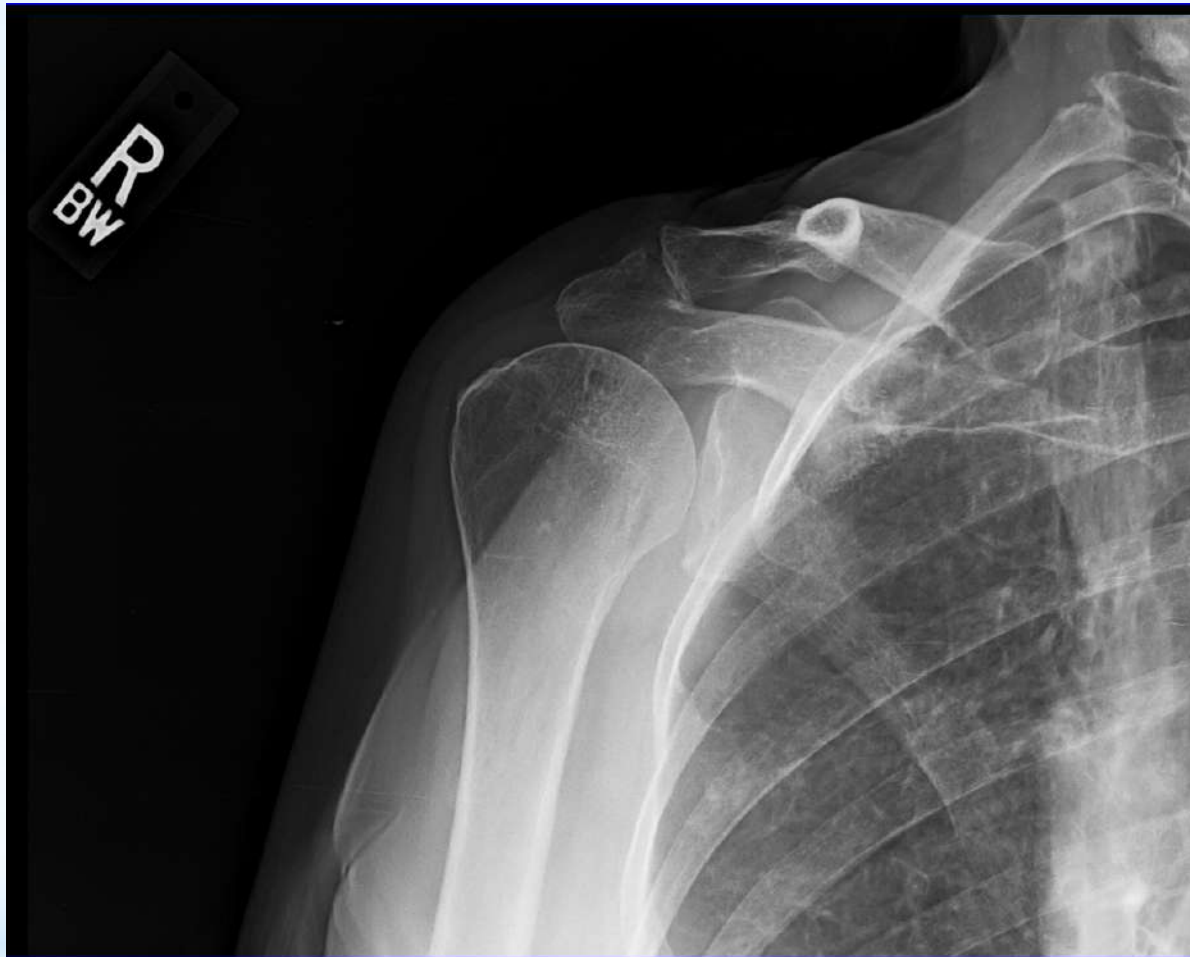
Surgical Repair

- * Peroneal nerve neurolysis
 - * Nerve was compressed but not damaged
 - * Scar tissue entrapment
- * ACL repair-BTB
- * LCL repair- Semitendinosus
 - * Complete avulsion at Fibula attachment
 - * 12mm lateral gapping
- * Posterolateral corner repair
 - * Biceps Femoris

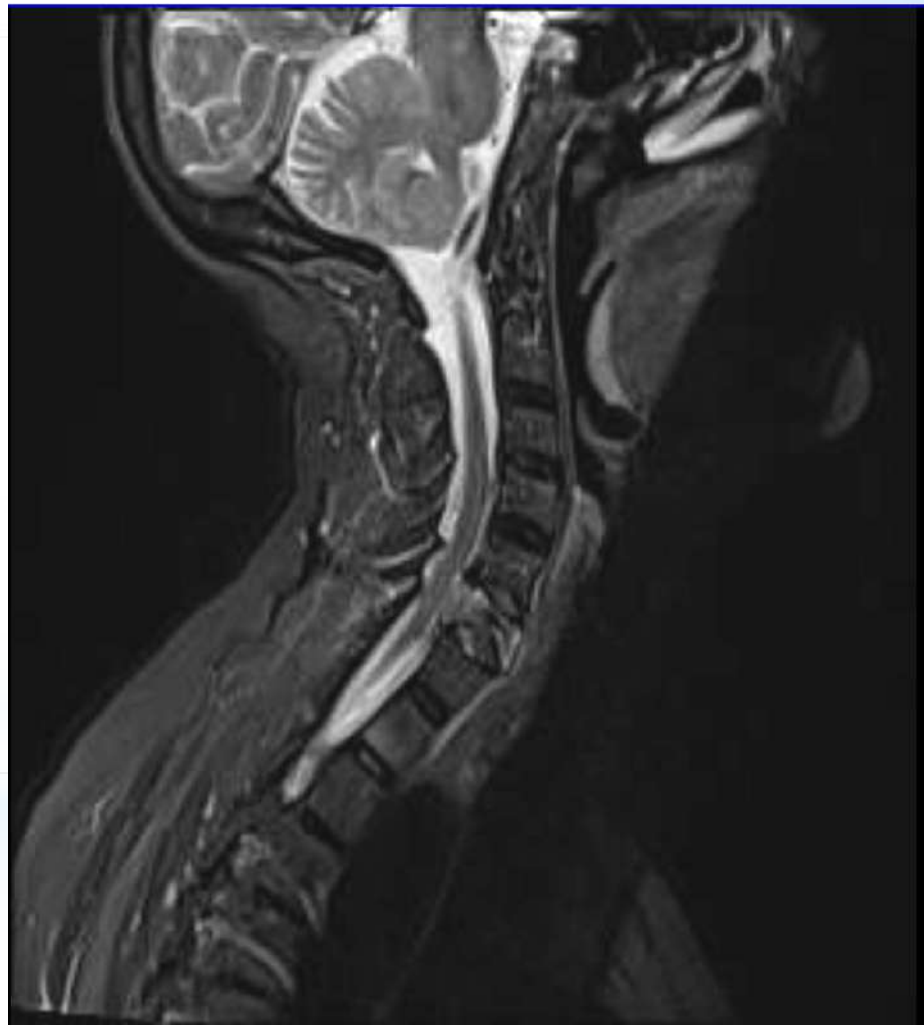
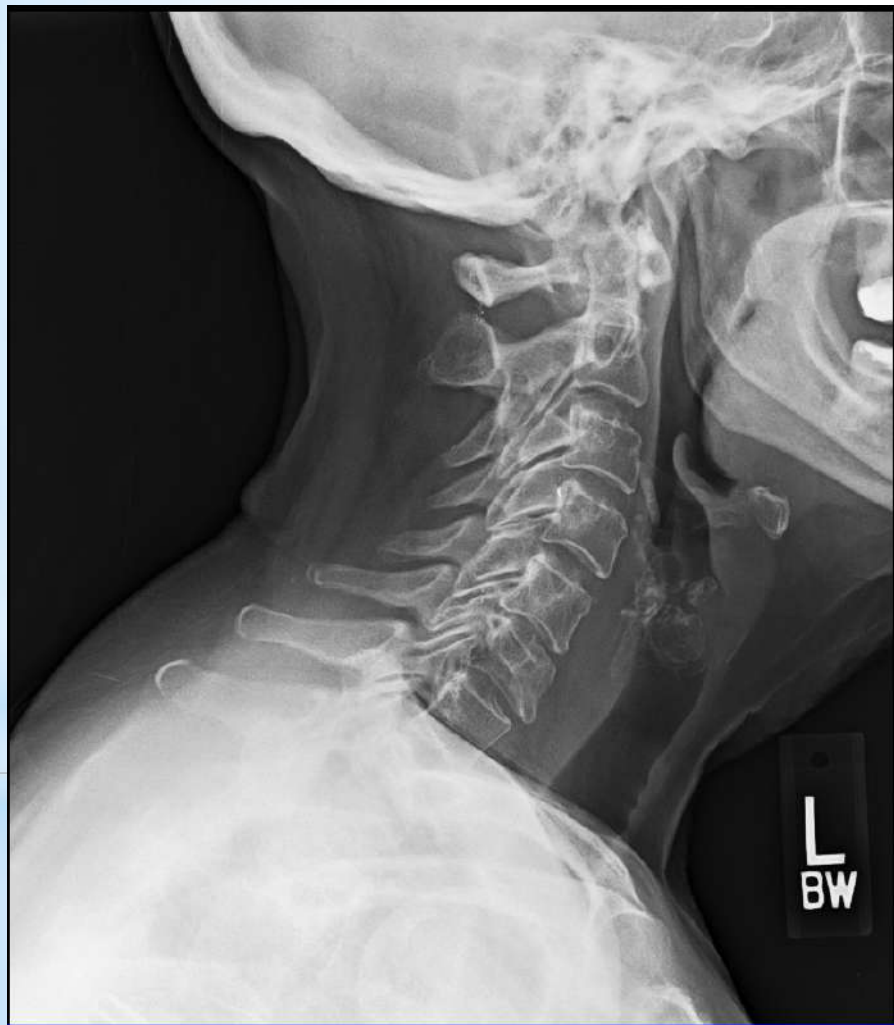**Red flag takeaway:
Not all joint injuries are created equal.**

- * 64-year-old female, with 1 month of “right shoulder pain”
- * Describes sharp stabbing pain along the posterior aspect of her shoulder, shoots into her upper arm.
- * She notes pain primarily at nighttime.
- * She notes the majority of her symptoms seems to be when she is lifting or gripping with the right arm, especially overhead.





- * Subacromial injection provided no relief, pain worsened
- * I love steroid injections.
 - * Either diagnosis is wrong, or the patient is unreliable



- * 40 year smoking history
- * Stage 4 non-small cell lung cancer
- * Pathologic fracture at C6, lytic involvement at C5, pathologic fracture at T1
- * Corpectomy with cage, radiation

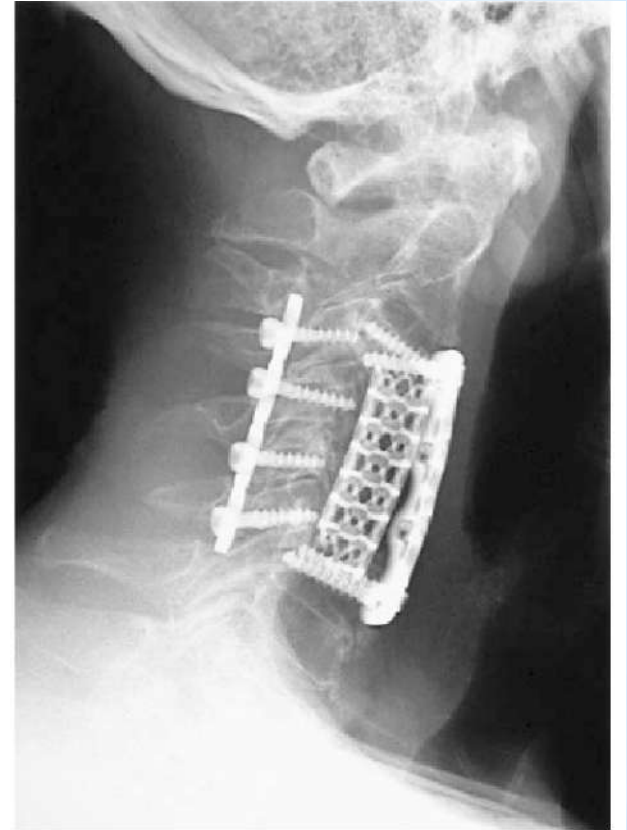


Fig. 4. Beddoomak demonstrating a corpectomy. Postoper

Red flag takeaway:

If the treatment is adequate and symptoms continue, diagnosis may be incorrect

- * 21-year-old male, low back pain since increasing activity in the gym x 1 month
- * Previous history of low back pain
- * Previous MRI showed mild disc herniations, stenosis
- * Symptoms improved previously with medicine, therapy, time



* When should you order further imaging?

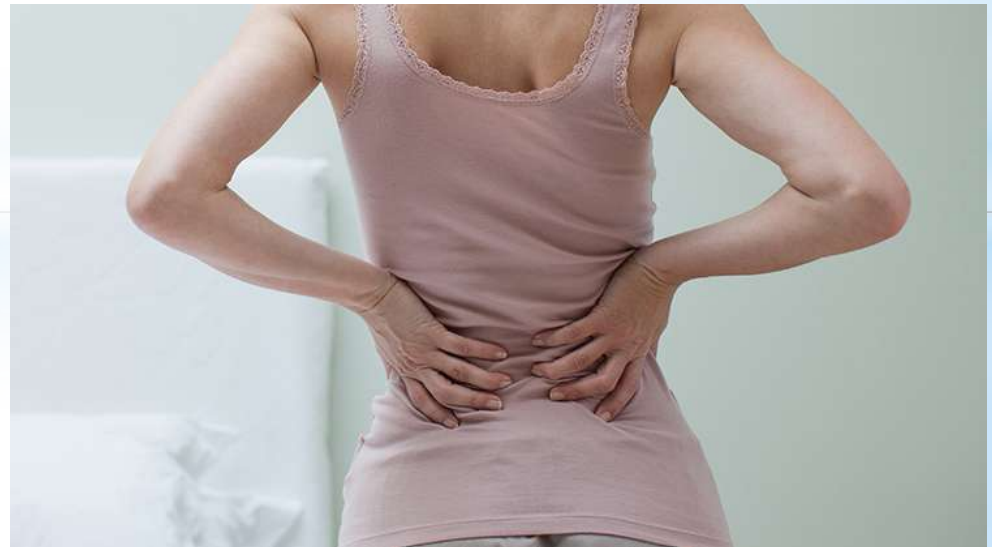* **If it will change how I will treat the patient.**

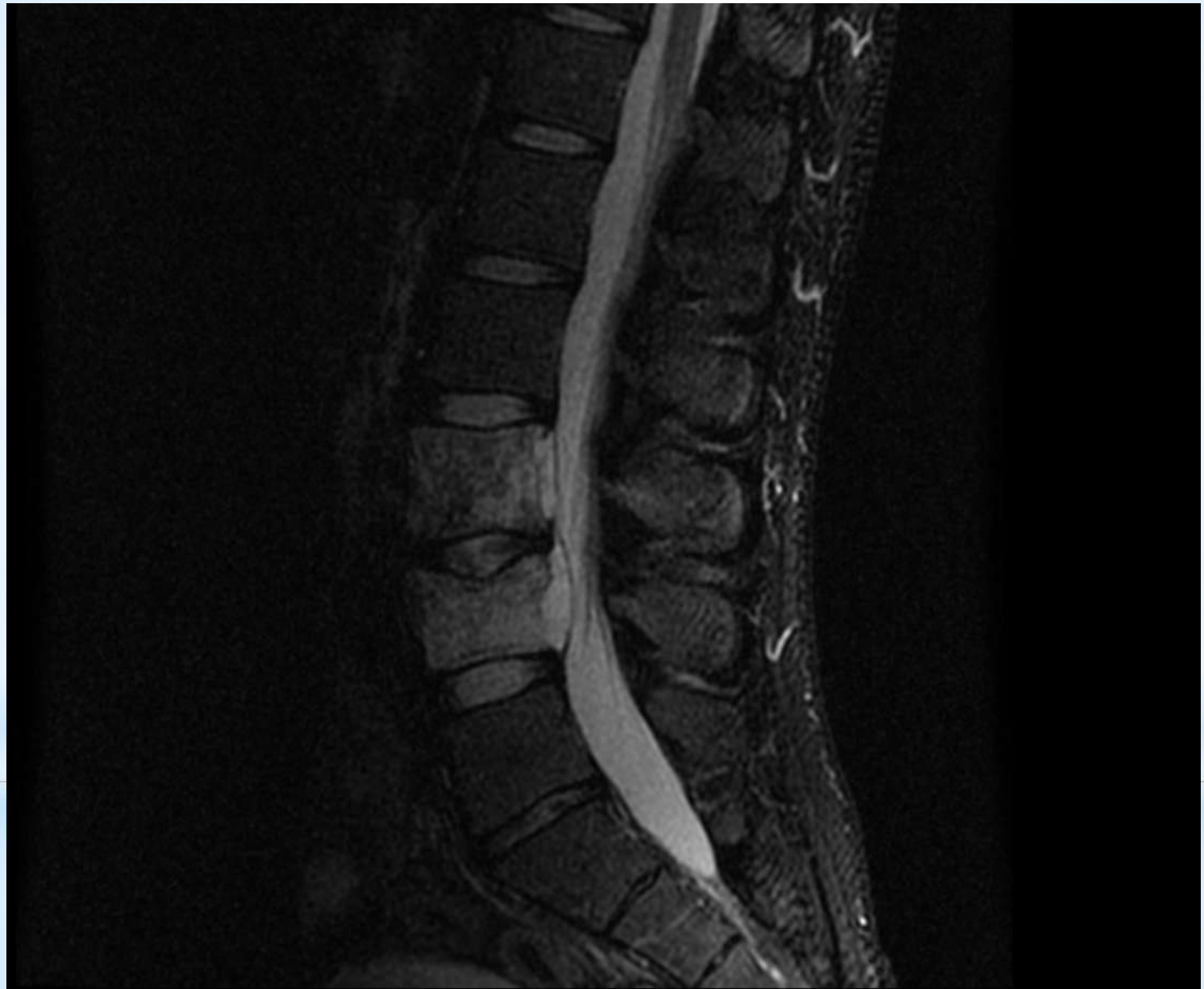* This patient:

* Significant midline pain, L2-S1

* Very minimal to no pain over paraspinals

* Very irritable on SLR, valsalva







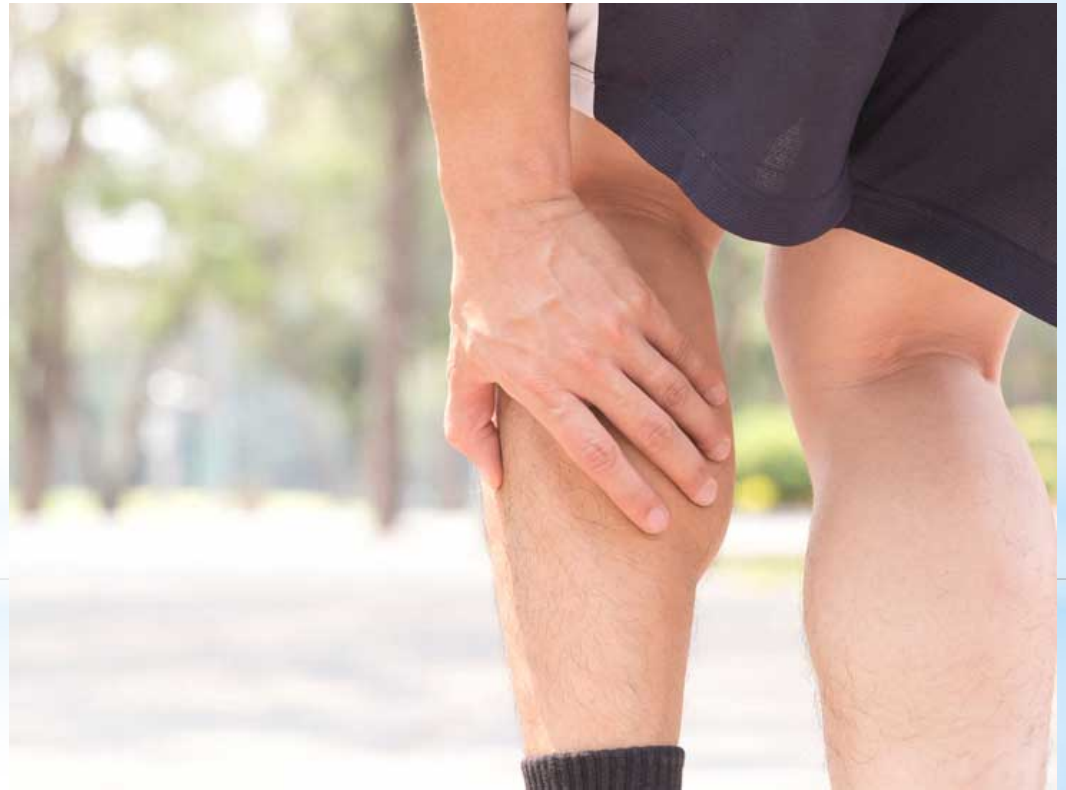- * Refer to Ortho Oncology, biopsy etc.
- * Dx: Chordoma
 - * Embryonic cells that remain in the spine/skull can sometimes differentiate into cancer
 - * Treatment is the same: resection, radiation, close monitoring
 - * High reoccurrence rate
- * Unknown results

Red flag takeaway:

Past performance is not an indication of future success

Case #5

- * 66-year-old male presents for evaluation of “right leg pain”
- * On/off pain for a number of months
- * “12/10” pain

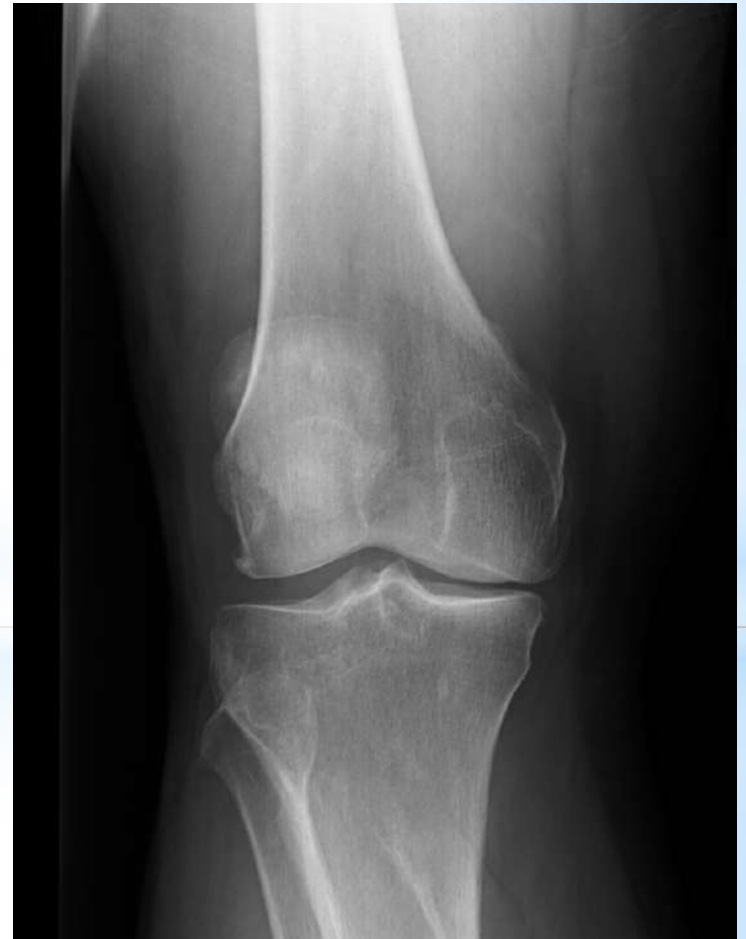
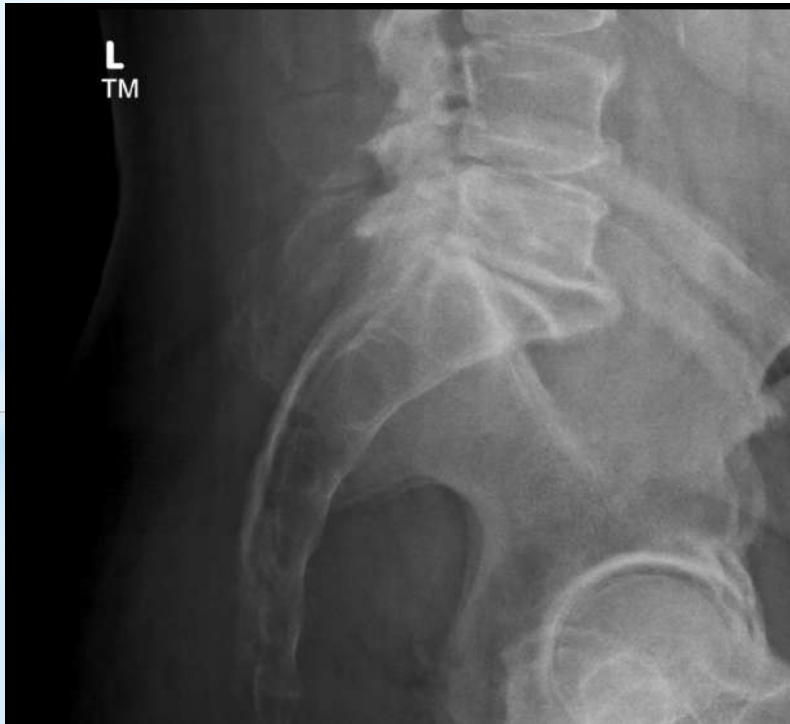
*Timeline

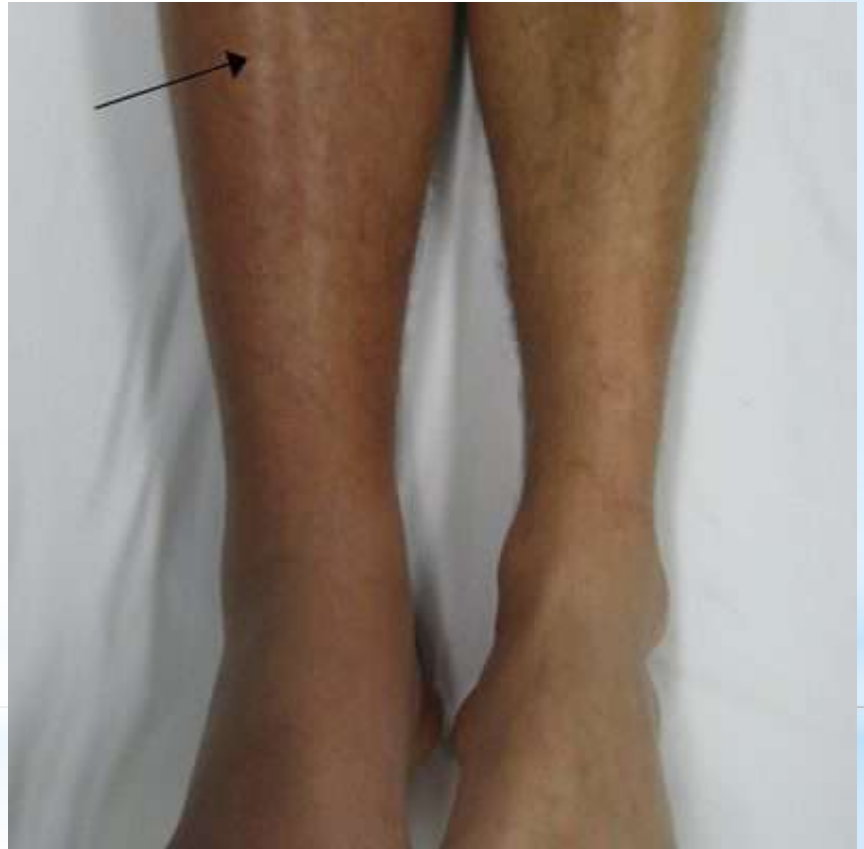- * For the past few years:
 - * Seeing knee surgeon for osteoarthritis, treatment with shots, etc.
- * 3 months prior:
 - * Saw spine specialist for right-sided low back pain
 - * Recent MRI, <3 months showed significant degenerative changes with primarily **right-sided stenosis/nerve impingement**
- * 1 month prior:
 - * Saw Orthopedic for thigh pain after “feeling a pop”, diagnosed with **right quad strain**
- * 3 weeks prior
 - * Saw Foot and Ankle Specialist
 - * MRI of the **right ankle** showed tearing in the peroneus longus, ankle joint ganglion and bony edema in the ankle

*Diagnosis List

- *1. Lumbar radiculopathy
- *2. Right quad strain
- *3. Right knee osteoarthritis
- *4. Peroneal tendon tear
- *5. Venous insufficiency



- * Pain and swelling in both legs, worse on right, along with skin changes consistent with venous stasis
- * TTP- Right lumbar, Right quad, Right calf, Right ankle
- * Recent SOB on exercise
- * Eval is important



* 6. Deep Venous Thrombosis

INTERPRETATION: Patent right common femoral and deep femoral veins. Extensive thrombosis involving the entire femoral vein extending into the peroneal and calf veins.

- * Occam's Razor: Entities should not be multiplied without necessity
 - * Translation: The simplest diagnosis is most likely the correct one
- * Hickam's Dictum: **A man can have as many diseases as he da*n well pleases.**

Red flag takeaway:

Consider Hickam's dictum over Occam's Razor

* Thank you.

* IG: The_Ortho_PA

Casselberry



2911 Red Bug Lake Road
Casselberry, FL 32707

(407) 699-9511

Office Hours: M-F, 8 a.m. – 5 p.m.

Orthopaedic Injury Walk-in Clinic Hours:

M-Th, 8 a.m. – 6 p.m.

Fri, 8 am – 4 p.m.

Sat, 9 a.m. – 1 p.m.

*Walk-ins Welcome

